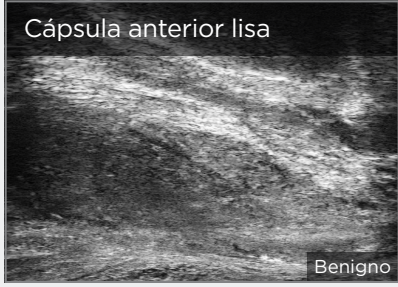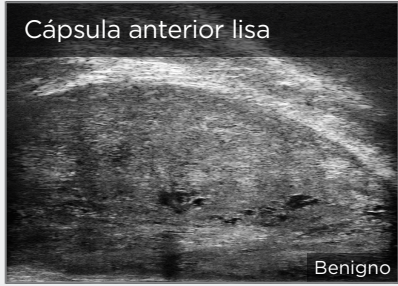
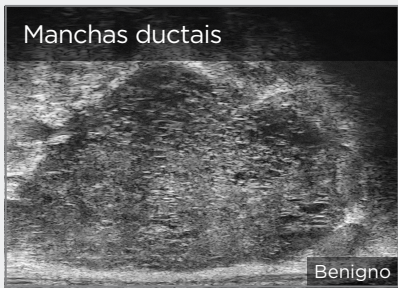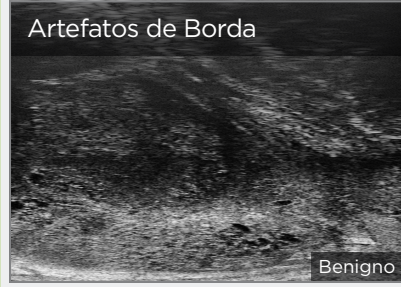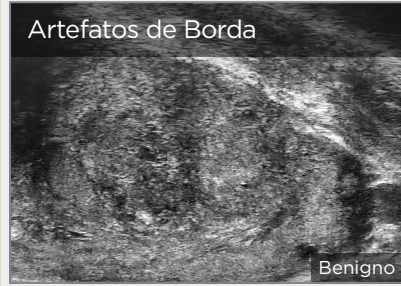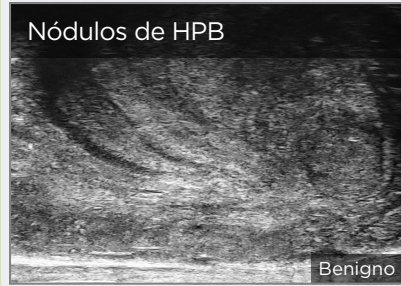


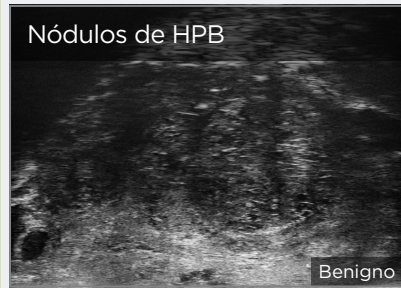SINAIS DE BAIXO RISCO

Manchas ductais em tecido Hiper ou Hipoecoico

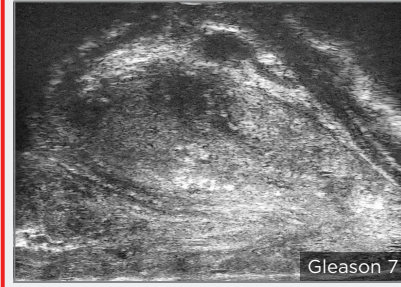
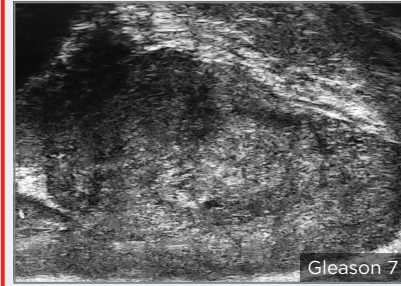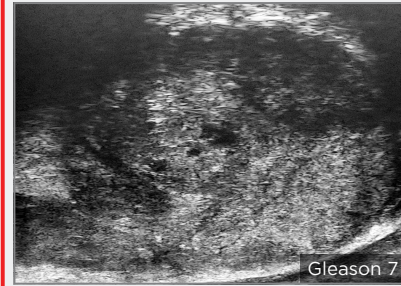
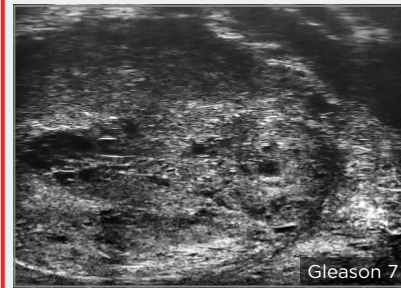


Problemas e Nódulos

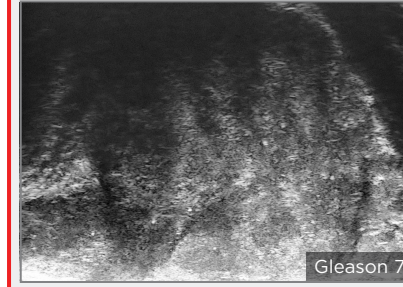
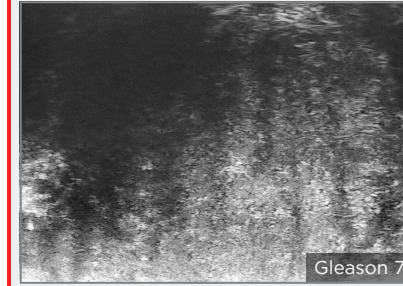
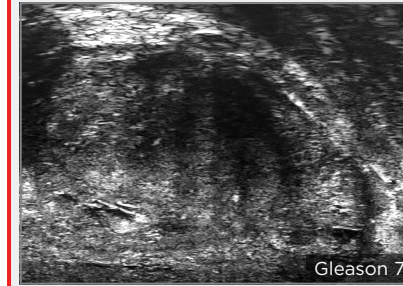



SINAIS DE ALTO RISCO (ORDEM ALEATÓRIA)

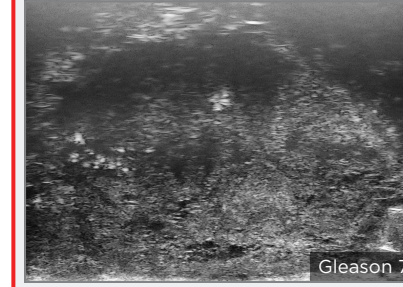

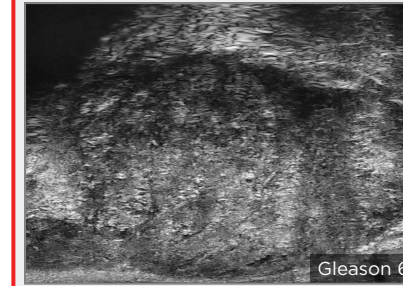
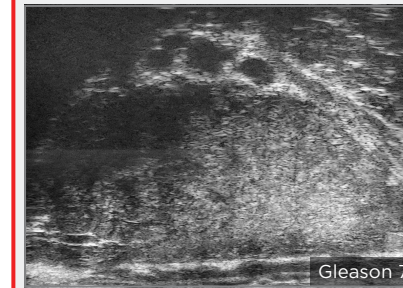
Lesões Focais Anteriores



Projeções Hipoecoicas Digitiformes



Nuvem de Tempestade



Lesões que Ocupam o Corno Anterior e a Próstata Anterolateral

